

**DISEASE SURVEY OF KLAMATH RIVER SALMONID
SMOLT POPULATIONS**

1992

Robert L. Walker

J. Scott Foott

U. S. Fish & Wildlife Service

California-Nevada Fish Health Center

Route 1, Box 2105

Anderson, CA 96007

Funded in part by:

Klamath River Basin Fisheries Task Force

April 1993

TABLE OF CONTENTS

ACKNOWLEDGEMENTS

ABSTRACT

INTRODUCTION

METHODS AND MATERIALS

- Sites
- Study Period and Groups
- Field Protocol
 - Iron Gate
 - Big Bar Trap
 - Upper and Lower Klamath Estuary
- Organosomatic Assays
- Microbiological Assays
 - Viral
 - Bacterial
 - Smears, Imprints, and Wet Mounts

RESULTS AND DISCUSSION

- Chinook
 - Hatchery Chinook
 - Natural Chinook
 - Unmarked Chinook Emigrants
 - Chinook Emigrants, Upper Estuary and Lower Estuary
- Coho
 - Hatchery Coho
 - Natural Coho
- Steelhead
 - Hatchery Steelhead
 - Natural Steelhead

SUMMARY

- Significant Results

REFERENCES

Appendices

Acknowledgements

This survey was funded in part by the Klamath River Basin Fisheries Task Force. We thank Mel Willis, CDFG pathologist, for his aid in sampling at Iron Gate Hatchery as well as the hatchery staff. The Coastal California Fisheries Resource Office (CCFRO), USFWS, was responsible for emigrant capture at the Big Bar trap. The California Department of Fish and Game, Arcata, was responsible for emigrant capture at various sites in the Klamath river estuary. In particular, we thank John Lang, Greg Goldsmith, and Mike Wallace for their help.

ABSTRACT

Juvenile chinook (*Oncorhynchus tshawytscha*), steelhead (*O. mykiss*), and coho (*O. kisutch*) of hatchery and natural origin were examined for selected pathogens at several locations during their emigration down the Klamath River. Health condition was ascertained by organosomatic analysis of sub-samples from each study group. The high incidence and intensity of *Nanophyetus salmincola* infection observed in the chinook and steelhead smolts indicate that this parasite may be a significant health factor to Klamath river stocks. *Renibacterium salmoninarum* was detected in hatchery coho, hatchery steelhead, and mixed chinook from the Klamath River estuary. An unidentified myxosporean parasite was observed in kidney tubules of chinook and coho. *Ceratomyxa shasta* spores were detected in juvenile chinook from the Klamath River estuary, but were not detected in any other fish examined in the study. Emigrants demonstrated physical signs consistent with smoltification and the rigors of migration.

INTRODUCTION

The Klamath River watershed drains approximately 14,400 km² in southern Oregon and 26,000 km² in northwestern California. Mitigation hatchery programs in the basin currently release millions of juvenile salmonids (smolts) into the Klamath and Trinity Rivers. Despite these programs, salmon and steelhead runs have undergone serious declines due to a variety of factors including water diversion, sedimentation of stream beds, and harvest (Calif. Advisory Comm. on Salmon and Steelhead, 1988). Disease can also play a major role in smolt migration success. The Klamath and Trinity River systems contain a host of endemic fish pathogens including Infectious Hematopoietic Necrosis Virus (IHNV), *Renibacterium salmoninarum* (BKD causative agent), and *Ceratomyxa shasta* (Hedrick et al. 1987, Manzer 1991, Hendrickson et al. 1989). Knowledge of the type and incidence of pathogens affecting Klamath River smolts may provide insight into the general health of emigrants and any role disease may be playing in smolt survival.

This report describes the results of a 1992 disease survey performed on natural chinook salmon (*Oncorhynchus tshawytscha*), coho salmon (*O. kisutch*), and steelhead trout (*O. mykiss*) emigrants and hatchery chinook, coho, and steelhead juveniles. Hatchery fish were examined at Iron Gate Hatchery prior to release. Hatchery and natural emigrants were collected with a rotary trap in the Klamath River. Chinook emigrants were also collected by seining in the Klamath River estuary. Samples collected from each group were diagnosed for pathogens and subjected to organosomatic analysis to monitor general health. Significant pathogens detected in the survey included *R. salmoninarum*, and metacercaria (presumptively identified as *Nanophyetus salmincola*).

METHODS AND MATERIALS

SITES

Iron Gate Hatchery (IRG) salmonids were examined no more than 3 weeks prior to their release. The hatchery is operated by the California Department of Fish and Game (CDFG) on a combination of CDFG departmental funds and Pacific Power and Light Company mitigation funds. The hatchery is located at river kilometer (rkm) 306 on the Klamath River (Fig. 1) and rears fall chinook salmon, coho salmon, and steelhead trout. These fish are the progeny of Klamath River adults captured and spawned at IRG.

The Big Bar rotary screw trap (BBT) located on the Klamath River at rkm 81, and operated by the U.S. Fish and Wildlife Service (USFWS), was used to capture both hatchery and natural emigrant salmonids (Figure 1). Natural fish were defined as the progeny of river or tributary spawning adults which had reared as juveniles in these environments regardless of parental genetics (Bjornn 1977). The rotary screw trap (2.44 m dia.) was fished to a depth of 1.22 m, sampling 2.34 m² of the thalweg (Craig, 1991).

Juvenile chinook samples from sites in the upper (west of the Highway 101 bridge to Hunter Creek) and lower (west of Hunter Creek to the Pacific Ocean) Klamath River estuary were collected during beach seining operations by the Arcata office of the California Department of Fish and Game under the direction of Mike Wallace (Fig. 2).

STUDY PERIOD & GROUPS

IRG fall chinook were released at twilight in groups of approximately 300,000 fish from June 4 through June 15, 1992. Coded wire tagged (CWT) fish were released on June 8, 1992. IRG fall chinook were examined on June 8, 1992 at the hatchery. Emigrant CWT IRG chinook were examined at BBT on June 23 (15 d post-release) and throughout the month of July 1992 (23-37 d post-release). Natural chinook juveniles were examined at BBT on May 11 and June 5, 1992. Chinook samples from the upper estuary (UE) were collected on May 11, June 1, and October 7, 1992. Chinook samples from the lower estuary (LE) were collected on June 11, July 15, and October 8, 1992.

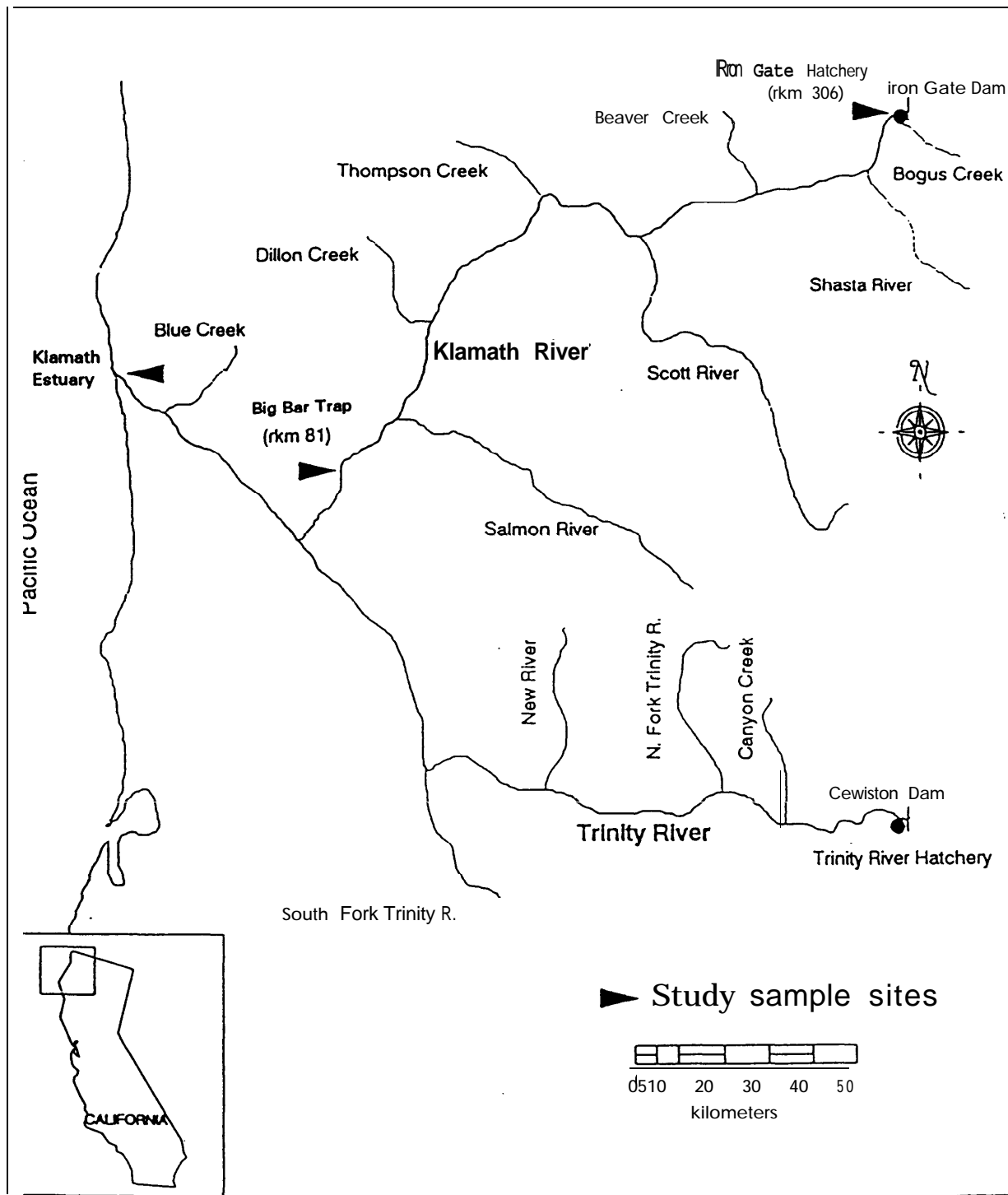


Figure 1. Study sampling sites at Iron Gate Hatchery, Big Bar Trap, and Klamath River estuary (modified from map prepared by Coastal California Fishery Resource Office).

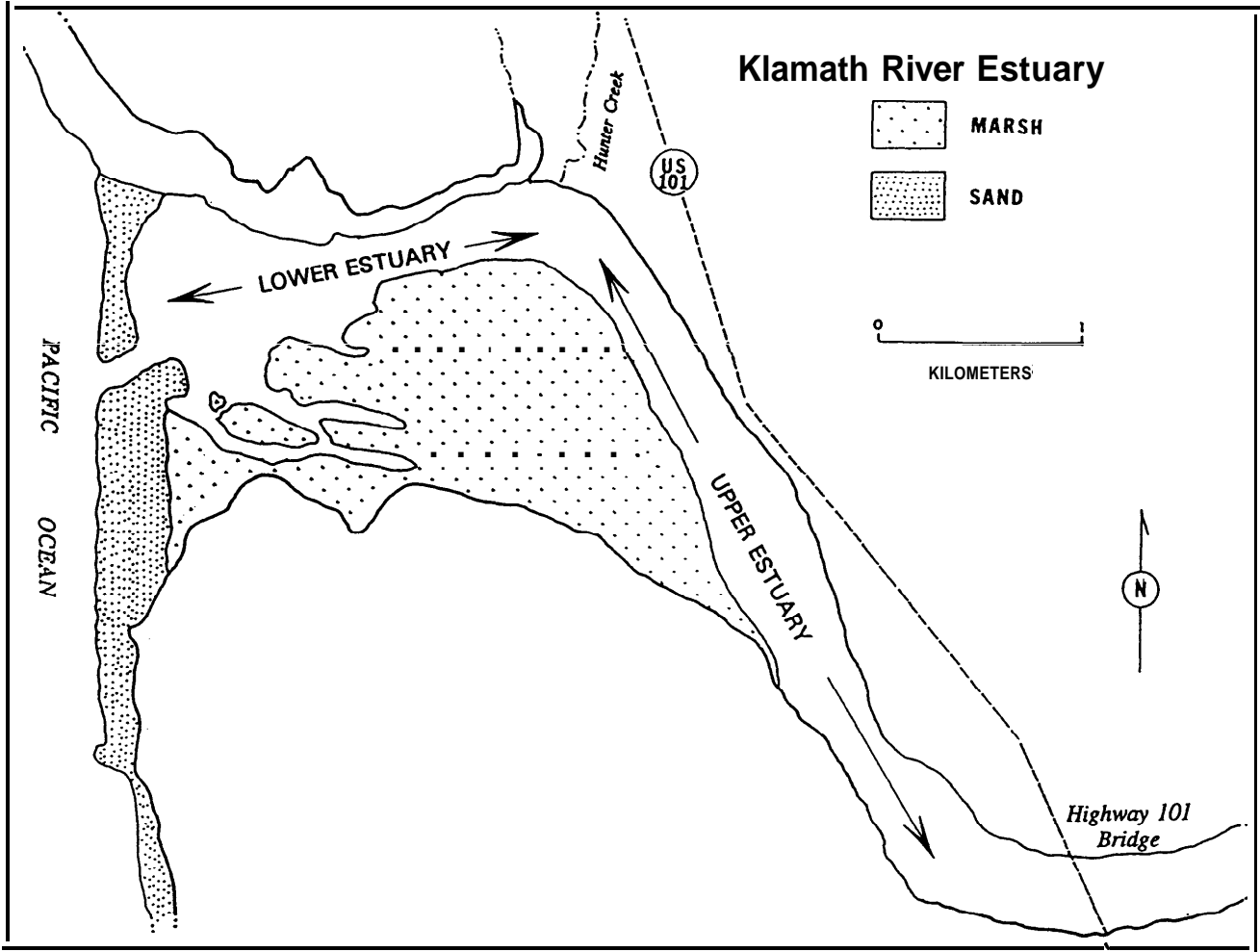


Figure 2. Study sampling sites in the Klamath River estuary (modified from map prepared by California Department of Fish and Game, Arcata).

Hatchery Coho juveniles were examined on March 9, 1992 at IRG 17 d prior to their release from the hatchery. Emigrant IRG coho were examined at BBT on May 11 (46 d post-release) and throughout the month of June 1992 (67-96 days post-release). Natural coho salmon juveniles were sampled at BBT throughout May and June 1992.

IRG steelhead were examined only at the hatchery, on the day of their release (May 19, 1992). In 1992, none of the approximately 48,000 yearling steelhead released from IRG were marked. Trapping data supplied by Coastal California Fisheries Resource Office (CCFRO) indicates that the peak of the hatchery steelhead emigration passed BBT from June 2 to June 4, 1992. During this three day period, a combined total of 54 yearling and two year old steelhead were captured. Sampling at this time was not possible due to a scheduled sampling of broodstock for the Nevada Department of Wildlife, and diagnostic work for the endangered Sacramento River winter run chinook salmon recovery program. During no other three day period were a total of 20 yearling steelhead collected. Difficulty was experienced in holding fish from June through July due to high river temperatures. During the June 5, 1992 sampling at BBT, water temperatures in excess of 23 C resulted in extreme heat stress and mortality of 15 steelhead prior to their examination. Due to the low numbers of hatchery fish released, lack of distinguishing mark, difficulty in holding fish due to high water temperatures, and conflicting schedule obligations IRG steelhead were not sampled at BBT. Natural steelhead were sampled at BBT on June 5, 1992.

FIELD PROTOCOL

Iron Gate (IRG)

A total of 60 fish per species were unbiasedly netted from several regions of at least 2 raceways and euthanized by an overdose of MS-222 (Argent Chemical Laboratories, Redmond, Washington). The caudal peduncle was severed for preparation of blood smears. Skin scrapings and excised gill filaments were immediately examined for parasites by phase microscopy. Kidney and spleen tissue for viral screening was aseptically dissected from each fish with sterile forceps and placed in whirl-pak bags (Cole-Parmer Instrument Co., Niles, Illinois). Tissues from two fish were pooled into one bag and held on ice without freezing until processed at the laboratory. Lower intestines for parasite examination and additional kidney tissue for Enzyme Linked Immunosorbent Assay (ELISA) or Direct Fluorescent Antibody Test (DFAT) were placed in tubes and held on ice. Tissues for histological examination were dissected and immediately placed in fixative. Imprints of kidney tissue on 75 x 25 mm slides were fixed in methanol. Twenty of the 60 fish sampled were used for organosomatic analysis.

Big Bar Trap (BBT)

Juvenile fish captured at BBT were held in-situ for up to 3 days in liveboxes. The captured fish were released if fewer than 20 smolts of given sample group were collected in a 3 d period. In mid-June, it became apparent that some study groups were not being captured in numbers sufficient to meet the above sampling criteria. We then requested that Greg Goldsmith and John Lang (CCFRO) fix and freeze any hatchery identified smolts. These samples were later shipped to the California-Nevada Fish Health Center (CA-NV FHC) for analysis. Hatchery chinook were identified by adipose fin clip. Emigrant IRG coho were identified by size (being much larger than natural coho in the river at the same time). Chinook (referred to as unmarked) which exhibited size, scale loss, and fin erosion similar to marked hatchery fish in the river at the time of capture were also collected. Natural steelhead and coho were selected on the basis of size (smaller than hatchery fish), and silver coloration. Natural chinook were collected at BBT prior to the hatchery

release of the fall chinook juveniles.

Procedures for field examination of captured smolts were similar to those described above. The organosomatic analysis was performed on the first 20 fish per group captured at the trap.

Upper and Lower Klamath Estuary (UE and LE)

Estuary chinook were sampled on 3 occasions at each study area (upper and lower estuary). In May, June, and October, heads of fish collected were preserved in 70% isopropanol for wet mount examination of gills. Carcasses were frozen, and mailed on ice to CA-NV FHC for examination. On July 15, 1992, fish were examined at the site of collection in the LE.

Procedures for field examination of captured smolts were similar to those described above. The organosomatic analysis was performed on the first 20 fish captured at the LE site on July 15.

ORGANOSOMATIC ASSAYS

A necropsy based fish condition assessment system developed by Ron Goede of the Utah Division of Wildlife Resources (Goede and Barton 1987) was modified for the smolt organosomatic assays (Foott 1990). The organosomatic assay is a method for ordered observation and reporting of the gross morphology of selected organs, hematological parameters, and size criteria of each individual in a 20 fish sample (Appendix 1). A numeric "severity" score (0,1,2,3) is assigned to each tissue where zero is normal and 3 represents severe abnormality. All of the fish's tissue scores are tallied to obtain an abnormality score (AS). A low AS represents an apparently healthy fish. The mean sample AS is a relative health indicator of a population and can be used for comparison between populations. Those tissues which showed abnormality in >10% of the fish were reported as "ABNORMAL TISSUES" in the organosomatic tables. A Lotus 1-2-3[™] spreadsheet was developed to calculate the various indices. Electrical power to operate the centrifuge, balance, and phase microscope was supplied by an automobile battery through a power inverter (TrippLite, Chicago IL). Parametric data such as weight, length, condition factor (K), hematocrit, and plasma protein concentration were tested for significance by the Student's T-test.

MICROBIOLOGICAL ASSAYS

Viral

Kidney and spleen tissue (two fish pools) were placed in sterile whirl-pak bags, diluted 1:10 in Hank's buffered salt solution (HBSS), homogenized with a Stomacher[™] tissue homogenizer, and the homogenate centrifuged for 10 min at 3350 g at 4 C. Supernatant (250 µl) from two samples were combined to form a 4 fish sample pool and diluted 1:1 with 500 µl of an antibiotic solution (1000 IU Penicillin G, 1000 IU Streptomycin sulfate, and 2.5 µg Amphotericin B per milliliter).

Samples (100 µl) were inoculated onto pre-formed EPC and CHSE-214 cells in duplicate wells of a 96 well plate at a final dilution of 1:20 and 1:200. The remaining tissue pellet was used for the bacterial assays described below. After 45 min incubation, 100 µl of minimum essential media containing 4% fetal bovine serum (MEM-4) and the antibiotic mixture described above was added to each well. The plates were incubated for 18 d at 15 C and examined every 2-3 d for cytopathic effect (CPE).

Bacterial

After supernatant from the 2-fish kidney-spleen homogenate was removed for the viral assay, a sample of the tissue pellet was inoculated onto Brain Heart Infusion Agar, and incubated for 4 d at 20 C. Bacterial isolates which were motile, oxidase positive, fermentative, gram-negative rods were presumptively identified as *Aeromonas hydrophila*.

Smears screened for *Renibacterium salmoninarum* by DFAT were prepared from the tissue homogenate pellets, fixed in xylene, and stained with a fluorescent antibody conjugate specific for *R. salmoninarum* (Kirkegaard & Perry Labs). A Zeiss fluorescent microscope was used to scan 50 fields of each smear at 1000X magnification. The sample was considered positive for *R. salmoninarum* if cells of the proper morphology (as compared to positive controls) reacted with the conjugate.

Fish were also screened for *R. salmoninarum* using a double-antibody enzyme-linked immunosorbent assay (ELISA) described by R. Pascho and D. Mulcahy (1987). ELISA is a method for indirectly detecting infection, but does not necessarily indicate the presence of *R. salmoninarum* (unlike DFAT where the bacteria themselves are visualized). In this technique, a surface-bound antibody selectively extracts *R. salmoninarum* antigen from homogenized kidney extract. The captured antigen is then detected by addition of antigen-specific antibody conjugated with a horseradish peroxidase (HRP) color indicator. A color reaction is produced which is proportional to the amount of antigen present in the sample. Kidney tissue was diluted 1:7 in phosphate-buffered saline with 0.05% Tween 20, pH 7.4 (PBS-T20), homogenized, and heated at 100 C for 15 min. Kidney homogenate was centrifuged for 5 min at 9000 g. Supernatant was applied to duplicate wells of a 96 well immunoplate (Nunc) previously coated (16 h, 4 C) with a polyclonal antibody specific for a soluble antigen fraction of *R. salmoninarum* (Kirkegaard & Perry Labs), and incubated (3 h, 25 C). A HRP labeled polyclonal antibody specific for *R. salmoninarum* soluble antigen (Kirkegaard & Perry Labs) was applied to the immunoplate in protein blocking solution and incubated (2 h, 25 C). Unbound antibody, sample, and conjugate were removed after incubation by washing with 0.002 M imidazole buffered saline containing 0.02% Tween 20 (Kirkegaard & Perry Labs). The antigen-antibody complex was visualized by addition of ABTS peroxidase substrate system (Kirkegaard & Perry Labs). Color development was stopped after 20 min at 37 C at by the addition of ABTS stop solution (Kirkegaard & Perry Labs) diluted 4:1 with deionized water. Absorbance was read at 405 nm. The high expense and lengthy preparation effort associated with ELISA precludes its use with small numbers of samples.

Smears, Imprints, and Wet Mounts

Blood smears and kidney imprints were air dried for 5 min, fixed in absolute methanol, and stained for 60 s in 0.5% (w/v in 70% ethanol) pinacyanol chloride (Sigma Chemical Co., Cat. No. P-0392). Thirty fields on each slide were examined for viral inclusions or parasites at 1000X oil immersion. Thirty fields of gill tissue wet mounts and kidney squash preparations were examined for *Nanophyetus salmincola* at 400X phase.

RESULTS & DISCUSSION

CHINOOK

Hatchery Chinook

IRG fall chinook were released at twilight in groups of approximately 300,000 fish from June 4 through June 15, 1992. A total of 62 fish were examined on June 8, 1992 at the hatchery. No significant viral, bacterial, or parasitic pathogens were detected in the fish at IRG (Table 1).

Emigrant IRG chinook were examined at BBT on June 23 (15 d post-release) and throughout the month of July 1992 (23-37 d post-release). Only 8 CWT fish were sampled, and of these 5 were available for organosomatic examination when we were present at BBT. Due to the small sample size, significance of organosomatic and pathogen prevalence data for this study group should be considered with caution. No significant bacterial pathogens were detected in the 8 adipose fin clipped fish sampled (Table 1). At this time of year, the only CWT chinook in the Klamath River should be from IRG (G. Goldsmith, CCFRO, pers. comm.). Spores of *Ceratomyxa shasta* were not observed in intestinal wet mount preparations from any of these fish. Metacercarial (encysted fluke) infection was observed by histological examination of gill and squash preparation of kidney tissues. Glochidial (larval mollusk) infection was observed by wet mount examination of gill. In both cases the infection by these parasitic organisms appeared to be light, and neither were detected in wet mount and histological examinations of hatchery fall chinook at time of their release. Presumably, infection by metacercaria and glochidia occurred during their migration downstream to BBT. Multinucleated parasites were observed within the lumen of kidney tubules in histological sections from 1 of 3 fish. No lesions were associated with these intraluminal parasites, which are presumed to be plasmodial stages of a coelozoic Myxozoan. The isolation of *Aeromonas hydrophila* from fish both at IRG and BBT is not unusual as this ubiquitous aquatic bacterium is regularly isolated from asymptomatic fish, and does not necessarily suggest bacterial disease.

The metacercaria observed were presumptively identified as *Nanophyetus salmincola* and the Glochidia as *Margaritifera margaritifera*, based on parasite morphology, site of infection, geographic location, and host species (Hoffman 1970, Jennings and Hendrickson 1982, Karna and Millermann 1978).

Salmonids are one intermediate host of the digean trematode, *Nanophyetus salmincola*, the final host being a fish-eating mammal. Eggs, shed with the final host's feces, hatch into free-swimming miracidia and infect aquatic snails of the genus *Oxytrema*. Free-swimming cercaria later leave the snail and penetrate the fish's skin. The parasite, now referred to as metacercaria, enters the circulatory system, encysts in various tissues, and stays with the fish for its entire life. *Nanophyetus salmincola* is itself parasitized by the rickettsial organism *Neorickettsia helminthoeca* which causes "salmon poisoning" in canines (Farrell et al. 1964). While metacercaria elicit little inflammation in fish, the parasite cysts cause obstruction and pressure injury to infected tissues (Wood and Yasutake 1956).

The freshwater mussel, *Margaritifera margaritifera*, releases immobile glochidia into the river current during early spring. If glochidia encounter the gills of a fish, they attach themselves to the host and become encysted. Over the course of 12 weeks to a year (temperature dependent), the glochidia develop into a juvenile mussel, excyst from the host, and convert to a benthic, free-living form (Young and Williams 1984). Infection by glochidia reduces respiratory efficiency due to

blood vessel blockage and hyperplasia of lamellar epithelium. When the developed juvenile mussel excyst, hemorrhage and secondary infection from the wound can occur (Meyers et al. 1980). In laboratory experiments, fish heavily infected with glochidia often die either due to asphyxiation or ionic imbalance (Young & Williams, 1984).

Low abnormality scores (AS) for the fish examined at IRG and 5 fish examined at BBT suggest that they were in good health (Table 2). Silver coloration was observed in 100% of the fish sampled at both sites. Mesenteric fat was observed in 100% of the fish at IRG, but was seen in only 40% of the fish sampled at BBT. Mean condition factor (K) was significantly higher ($P < 0.05$) for hatchery fall chinook sampled at IRG than those captured at BBT. Reduction in K and mesenteric fat may be due to physical demands of migration, slow adaptation of the hatchery fish to natural forage, and metabolic demands of smoltification. Smolts generally show a reduction in condition factor and are silver (Hoar 1988). Although plasma protein levels were shown to be significantly greater in the fish sampled at the hatchery than at the trap ($P < 0.01$), values measured at both sites were well within normal physiological range.

TABLE 1. Iron Gate Hatchery Fall Chinook Juveniles: Prevalence of infection for Infectious Hematopoietic Necrosis Virus (IHNV) in four fish pool kidney-spleen samples and Erythrocytic Inclusion Body Syndrome (EIBS) inclusions in individual blood smears. Bacteria in individual fish kidney samples or two fish kidney-spleen pools. Parasites in individual smears, wet mounts, and histological samples. Direct Fluorescent Antibody Test (DFAT) was used to detect *Renibacterium salmoninarum*. A total of 62 hatchery chinook were sampled on June 8, 1992 at Iron Gate Hatchery (IRG). Eight adipose fin-clipped fish were sampled during emigration at the Big Bar Trap (BBT) on June 23, 1992 (15 d post-release), and throughout July (23-37 days post-release). Reported as number positive over number sampled (% positive).

	IRG	BBT
IHNV	0/15 (0)	ND
EIBS	0/62 (0)	ND
BACTERIA		
<i>R. salmoninarum</i>	0/30 (0)*	0/8 (0)
<i>Aeromonas hydrophila</i>	2/15 (13)*	2/5 (40)
PARASITES		
Skin:	0/10 (0)	ND
Gill:		
Glochidia	0/23 (0)	1/7 (14)
Metacercaria+	0/23 (0)	4/7 (57)
Intestine:	0/30 (0)	0/5 (0)
Blood:	0/62 (0)	ND
Kidney:		
Metacercaria+	0/19 (0)	3/6 (50)
Myxosporean++	0/19 (0)	1/3 (33)
ND	Not done.	
*	Two fish pool, kidney-spleen.	
+	Presumptively identified as <i>Nanophyetus salmincola</i> .	
++	Unidentified myxosporean.	

TABLE 2. Iron Gate Hatchery Fall Chinook Juvenile Organosomatic Analysis Data:
Twenty chinook were examined at Iron Gate Hatchery (IRG) on June 8, 1992. Five
coded wire tagged chinook were examined at the Big Bar Trap (BBT) on June 23,
1992 (15 d post-release). Percentages reflect the number of fish in sample which meet
the row criteria.

	IRG	BBT
CUMULATIVE ABNORMALITY SCORE	0.00	0.00
ABNORMAL TISSUES+	NONE	NONE
FAT LEVEL >0 (%)	100	40
SILVERED (%)	100	100

CONDITION FACTOR (k)		
mean	0.9551**	0.8307
std	0.1120	0.0685
cv	11.73	8.25
LENGTH (mm)		
mean	88.90	98.20**
std	8.09	6.11
cv	9.10	6.22
WEIGHT (g)		
mean	6.89	8.06
std	2.36	2.29
cv	34.34	28.44
HEMATOCRIT		
mean	42.10	41.50
std	4.70	4.03
cv	11.16	9.71
PLASMA PROTEIN		
mean	4.94*	3.92
std	0.49	0.25
cv	9.88	6.33

** Significantly greater (P <0.05)

* Significantly greater (P <0.01)

+ Tissues listed if >10% of sample had abnormal rating in that tissue.

std Standard deviation.

cv Coefficient of variation.

Natural Chinook

Natural chinook juveniles were examined on May 11, and June 5, 1992 at the BBT. A total of 58 fish were sampled. No viral pathogens were detected in these fish (Table 3). Spores of *Ceratomyxa shasta* were not observed in intestinal wet mount preparations from any of these fish. Enzyme-linked immunosorbent assay (ELISA) showed only 8% of the fish sampled to have *Renibacterium salmoninarum* antigen levels greater than 2 standard deviations above normal reference tissue, and none had antigen levels suggestive of an active infection (antigen positive designation). Presence of the *R. salmoninarum* organism was not confirmed by direct fluorescent antibody test (DFAT).

Metacercarial (presumptively *N. salmincola*) infection was observed in 67% of gill samples and 13% of kidney examined. All kidney sample metacercarial infections appeared to be light (5 parasites per sample). Of the gill samples where metacercaria were found, 29% appeared to have a heavy (5 parasites per sample) infection. Metacercarial cysts in the gill were observed to be lodged in afferent filament arteries and occasionally in the vascular space of the lamellae. Often the supporting filament cartilage was disrupted by the encysted metacercaria. No signs of associated inflammation or venous blockage was seen. The gills may have been sites of initial colonization by metacercaria, which could explain the disproportionately high intensity of infection found there. Glochidia were observed in only 1 of 58 gill samples. Histological examination of kidney tissue showed 4 of 22 samples to contain focal Glomerulonephritis (GNR) with no associated parasites. It is possible that soluble antigen from infecting parasites or bacteria could have resulted in the GNR. Antibody-soluble antigen complex deposition and resultant complement activation can cause such lesions (Slauson & Cooper, 1982). Intraluminal myxosporean parasites were seen in 32% of the kidney sections examined from this group. No lesions were associated with these intraluminal parasites.

Anemic gill coloration was observed in >10% of the June 5 sample, possibly due to heavy metacercarial infection (Table 4). Mesenteric fat was visible in 70% of the fish sampled on May 11, and 65% of the fish sampled on June 5, 1992. Silver coloration was observed in all fish. Fish from the earlier capture (May 11, 1992) were significantly greater in length and weight than fish sampled later (June 5, 1992). Although plasma protein levels were shown to be significantly greater in the fish sampled on May 11 than on June 5 ($P < 0.01$), values measured on both dates were well within normal physiological range.

Unmarked Chinook Emigrants

Unmarked chinook were captured at BBT throughout July 1993. The size and fin erosion observed in these fish was similar to that seen in adipose fin-clipped hatchery emigrants in the river at the same time. Although physical appearance suggests that they may have been hatchery fish, lack of fin mark makes their exact origin uncertain. A total of 52 fish were sampled. *R. salmoninarum* was not detected in these fish (Table 5). Metacercarial (presumptively *N. salmincola*) infection was observed in 90% of gill tissues examined by wet mount, and 33% of kidney tissues by squash preparation. Of the gill samples where metacercaria were found, 68% appeared to have a heavy infection. Histological examination of kidney samples showed 3 of 11 to contain focal granulomas without associated parasites. This "scar tissue" lesion is characteristic of a host response to *R. salmoninarum* (Young and Chapman, 1978) or parasite infection (Kent and Hedrick, 1985). Glochidial infection was observed in 42% of gill tissues examined (of which, 1 sample was heavily infected). Histological examination showed 7 of 11 kidney samples to contain intraluminal myxosporean parasites similar to those seen in hatchery chinook captured at BBT on June 23.

Mesenteric fat was visible in only 56% of the fish sampled, and silver coloration was observed in all fish (Table 6).

TABLE 3. Natural Klamath River Chinook Emigrants: Incidence of virus infection in four fish pool kidney-spleen samples and Erythrocytic Inclusion Body Syndrome (EIBS) inclusions in individual blood smears. *Renibacterium salmoninarum* in individual samples or 2 fish pooled kidney samples. Other bacteria in 2 or 4 fish kidney-spleen pools. Parasites in individual smears, wet mounts, and histological samples. Enzyme Linked Immunosorbent Assay (ELISA) and Direct Fluorescent Antibody Technique (DFAT) was used to detect *Renibacterium salmoninarum*. A total of 58 natural chinook were sampled during emigration at the Big Bar Trap on May 11 and June 5, 1992. Reported as number positive over number sampled (% positive).

	11MAY	5JUN	INCIDENCE
VIRUS	0/9	0/6	0/11 (0)
EIBS	0/10	0/30	0/40 (0)
BACTERIA			
<i>R. salmoninarum</i>			
ELISA: Antigen positive	0/36	ND	0/36 (0)
Antigen suspect	3/36	ND	3/36 (8)
DFAT	0/36	0/12+	0/58 (0)
<i>Aeromonas hydrophila</i>	7/9*	7/12+	14/21 (67)
PARASITES			
Gill:			
Metacercaria**	19/28	20/30	39/58 (67)
Glochidia	0/28	1/30	1/58 (2)
Intestine:			
Metacercaria***	0/20	1/27	1/47 (2)
Blood:			
	0/10	0/30	0/40 (0)
Kidney:			
Metacercaria**	4/30	3/22	7/52 (13)
Myxosporean++	5/14	6/22	11/34 (32)
ND	Not Done.		
+	Two fish pools.		
*	Four fish pools.		
**	Presumptively identified as <i>Nanophyetus salmincola</i> .		
++	Unidentified myxosporean.		
***	Unidentified metacercaria.		

TABLE 4. Natural Klamath River Chinook Emigrant Organosomatic Analysis Data:
Twenty natural chinook were examined at the Big Bar Trap on May 11, and June 5,
1992. Percentages reflect the number of fish in sample which meet the row criteria.

	11MAY	5JUN
CUMULATIVE ABNORMALITY SCORE	0.00	0.15
ABNORMAL TISSUES+	NONE	GILL
FAT LEVEL >0 (%)	70	65
SILVERED (%)	100	100

CONDITION FACTOR (k)		
mean	0.7200	0.8862*
std	.1170	0.0712
cv	16.26	8.04
LENGTH (mm)		
mean	102.25*	86.25
std	12.07	7.76
cv	11.80	8.99
WEIGHT (g)		
mean	7.93*	5.80
std	2.54	1.50
cv	32.00	25.84
HEMATOCRIT		
mean	45.22	44.55
std	5.18	4.46
cv	11.46	10.00
PLASMA PROTEIN		
mean	5.11*	4.22
std	0.62	0.49
cv	12.08	11.58

* Significantly greater (P <0.01)

+ Tissues listed if >10% of sample had abnormal rating in that tissue.

std Standard deviation.

cv Coefficient of variation.

TABLE 5. Unmarked Chinook Emigrants: Prevalence of infection for bacteria in individual fish kidney samples. Parasites in individual smears, wet mounts, and histological samples. Direct Fluorescent Antibody Test (DFAT) was used to detect *Renibacterium salmoninarum*. A total of 52 unmarked chinook were sampled during emigration at the Big Bar Trap throughout July. Reported as number positive over number sampled (% positive).

BACTERIA

R. salmoninarum 0/48 (0)

PARASITES

Gill:

Glochidia 21/50 (42)

Metacercaria* 37/41 (90)

Intestine: 0/48 (0)

Kidney:

Metacercaria* 13/39 (33)

Myxosporean+ 7/11 (64)

ND Not done.

* Presumptively identified as *Nanophyetus salmincola*.

+ Unidentified myxosporean parasite.

Chinook Emigrants, Upper Estuary and Lower Estuary (UE and LE)

Chinook were sampled in the UE on May 11, June 1, and October 7, 1992, and in the LE on June 11, July 15, and October 8, 1992 (Fig 2). An effort was made to collect fish exhibiting size and silver coloration suggestive of an age and physiological state similar to that seen in hatchery fish captured upstream. Due to mixing in the estuary of fish stocks from many sources, and the lack of fin marks on the majority of fish sampled, the exact race and origin of these fish is largely uncertain.

A total of 32 fish from the UE were examined (Table 7). ELISA showed 75% of the fish sampled to have *R. salmoninarum* antigen levels greater than 2 standard deviations above normal reference tissue, and 25% had antigen levels supporting an antigen positive designation. Presence of the *R. salmoninarum* organism was not confirmed by DFAT. Metacercarial (presumptively *N. salmincola*) infection was observed in 66% of gill, and 56% of kidney tissues examined. In the fish where metacercaria were found, 50% of the kidney samples and 26% of the gill samples appeared to have a heavy infection. Light glochidial infection was observed in 24% of gill tissues. *Diplostomulum spathaceum* metacercaria were observed in eye tissues from 1 of 29 fish sampled in the UE.

A total of 54 fish from the LE were examined (Table 8). ELISA showed 90% of the fish sampled to have *R. salmoninarum* antigen levels greater than 2 standard deviations above normal reference tissue, and 6% had antigen levels supporting an antigen positive designation. Presence of the *R. salmoninarum* organism was not confirmed by DFAT. Metacercarial (presumptively *N. salmincola*) infection was observed in 64% of gill, and 63% of kidney tissues examined. In the fish where metacercaria were found, 48% of the kidney samples and 41% of the gill samples appeared to have a heavy infection. Focal glomerulonephritis (inflammation of the glomerulus) was observed in 5 of the 49 kidney samples examined by histology, and was not associated with any parasites. Light glochidial infection was observed in 12% of gill tissues examined. Intraluminal myxosporean parasites were seen in 5 of the 9 kidney tissues examined histologically. No lesions were associated with these intraluminal parasites. *Diplostomulum spathaceum* was observed in eye tissues from 1 of 14 fish in the LE.

The range of salinity in the LE has been measured as approximately 12-25 ppt., and although the salinity in the UE periodically reaches highs of 20 ppt. (varying with fluctuations in tidal influence and weather), the saline portion of the UE is largely confined to the thalweg. Accordingly, the UE has a larger area which exists as freshwater for a greater proportion of time than does the LE (Mike Wallace, CDFG, pers. comm.). ELISA showed a higher percentage of fish in the UE to have *R. salmoninarum* antigen levels suggestive of an active infection (positive designation) when compared to fish from the LE. Kidney dysfunction may compromise the ability of heavily infected individuals to adapt to saltwater. Although the variable nature of salinity in the UE and LE makes correlation between infection level and saltwater adaptation of these fish difficult, the data suggest the possible segregation of heavily infected individuals to areas with accessible freshwater refugia.

Ceratomyxa shasta spores were detected in the intestine of 6% of the LE chinook examined. Although endemic to the Klamath River Basin (Hendrickson et al. 1989), spores of this myxosporean were not detected in any other fish examined in the study.

Mesenteric fat was not visible in any of the LE fish subjected to organosomatic analysis (Table 9). Silver coloration was observed in all fish. The mean condition factor (K) of 0.8663×10^{-5} was slightly higher than the average value of 0.8190×10^{-5} given for chinook (Piper et al 1982). The similarity of (K) from chinook sampled in the LE and natural chinook sampled at BBT suggest that these fish were of comparable condition.

TABLE 6. Unmarked Chinook Emigrant Organosomatic Analysis Data: Nine unmarked chinook were examined at the Big Bar Trap on July 1, 1992. Fish were selected on the basis of size and fin erosion (which was similar to that observed in coded wire tagged hatchery emigrants in the river at the same time). Percentages reflect the number of fish in sample which meet the row criteria.

CUMULATIVE ABNORMALITY SCORE	0.22
ABNORMAL TISSUES+	SKIN
FAT LEVEL >0 (%)	56
SILVERED (%)	100
-	
CONDITION FACTOR (k)	
mean	0.8698
std	0.0520
cv	5.98
LENGTH (mm)	
mean	103.78
std	4.10
cv	3.95
WEIGHT (g)	
mean	9.76
std	1.21
cv	12.42
HEMATOCRIT	
mean	45.20
std	3.54
cv	7.84
PLASMA PROTEIN	
mean	4.18
std	0.58
cv	13.95

+ Tissues listed if >10% of sample had abnormal rating in that tissue.
 std Standard deviation.
 cv Coefficient of variation.

TABLE 7. Chinook Emigrants, Upper Klamath Estuary: Incidence of infection for *Renibacterium salmoninarum* in individual fish kidney, and two fish pooled kidney samples. Parasites in individual smears, wet mounts, and histological samples. Enzyme Linked Immunosorbent Assay (ELISA) and Direct Fluorescent Antibody Technique (DFAT) was used to detect *Renibacterium salmoninarum*. A total of 32 chinook were sampled during emigration in the upper Klamath River estuary on May 11, June 1, and October 7, 1992. Reported as number positive over number sampled (% positive).

	11MAY	1JUN	7OCT	INCIDENCE
BACTERIA				
<i>R. salmoninarum</i>				
ELISA: Antigen positive	1/7	3/7	0/2	4/16 (25)
Antigen suspect	2/7	4/7	2/2	8/16 (50)
DFAT:	0/7	0/7	ND	0/14 (0)
PARASITES				
Gill:				
Metacercaria*	7/14	12/15	ND	19/29 (66)
Glochidia	1/14	6/15	ND	7/29 (24)
Eye				
<i>Diplostomulum sp.</i>	0/14	1/15	ND	1/29 (3)
Intestine:	0/14	0/16	0/2	0/32 (0)
Kidney:				
Metacercaria*	5/14	11/16	2/2	18/32 (56)
ND	Not Done.			
*	Presumptively identified as <i>Nanophyetus salmincola</i> .			

TABLE 8. Chinook Emigrants, Lower Klamath Estuary: Incidence of infection for *Renibacterium salmoninarum* in individual fish kidney, and two fish pooled kidney samples. Parasites in individual smears, wet mounts, and histological samples. Enzyme Linked Immunosorbent Assay (ELISA) and Direct Fluorescent Antibody Technique (DFAT) was used to detect *Renibacterium salmoninarum*. A total of 54 chinook were sampled during emigration in the lower Klamath River estuary on June 11, July 15, and October 8, 1992. Reported as number positive over number sampled (% positive).

	11JUN	15JUL	8OCT	INCIDENCE
BACTERIA				
<i>R. salmoninarum</i>				
ELISA: Antigen positive	1/7	2/31	0/11	3/49 (6)
Antigen suspect	6/7	24/31	11/11	41/49 (84)
DFAT:	0/7	0/31	ND	0/38 (0)
PARASITE				
Gill:				
Metacercaria*	8/14	32/41	1/3	37/58 (64)
Glochidia	4/14	2/41	0/3	6/58 (10)
Eye:				
<i>Diplostomulum sp.</i>	1/14	ND	ND	1/14 (7)
Intestine:				
<i>Ceratomyxa shasta</i>	0/14	3/30	0/10	3/54 (6)
Kidney:				
Metacercaria*	12/14	8/24	11/11	31/49 (63)
Myxosporean+	ND	5/9	ND	5/9 (56)
ND	Not Done.			
*	Presumptively identified as <i>Nanophyetus salmincola</i> .			
+	Unidentified myxosporean.			

TABLE 9. Chinook Emigrants, Lower Klamath Estuary Organosomatic Analysis Data:
Twenty chinook were examined from the Lower Klamath Estuary on July 15, 1992.
Due to mixing in the estuary of fish stocks from many sources, and the lack of fin
marks on the majority of fish captured, the exact race and origin of these fish is
largely uncertain. Percentages reflect the number of fish in sample which meet the
row criteria.

CUMULATIVE ABNORMALITY SCORE	0.30
ABNORMAL TISSUES+	NONE
FAT LEVEL >0 (%)	0.00
SILVERED (%)	100
CONDITION FACTOR (k)	
mean	0.8663
std	0.0747
cv	8.62
LENGTH (mm)	
mean	97.35
std	9.05
cv	9.29
WEIGHT (g)	
mean	8.09
std	2.01
cv	24.89
HEMATOCRIT	
mean	44.25
std	8.19
cv	18.51
PLASMA PROTEIN	
mean	3.83
std	0.76
cv	19.92

+ Tissues listed if >10% of sample had abnormal rating in that tissue.
std Standard deviation.
cv Coefficient of variation.

COHO

Hatchery Coho

Coho salmon were examined at IRG on March 9, 1992 (17 d prior to release). A total of 60 fish were sampled. No significant viral or parasitic pathogens were detected in the fish at IRG (Table 10). ELISA showed 17% of the fish sampled to have *R. salmoninarum* antigen levels greater than 2 standard deviations above normal reference tissue, and 10% had antigen levels supporting an antigen positive designation. The presence of the *R. salmoninarum* organism was confirmed by DFAT. *Yersinia ruckeri*, the causative agent of enteric redmouth disease (ERM), was isolated from 7% of the fish at the hatchery cultured for bacteria. However, no clinical signs of ERM were observed in these fish. It is doubtful that the level of *Trichodina* (an invasive protozoan which may cause irritation when occurring in large numbers) seen in the hatchery fish had much of an effect on their health.

Hatchery coho emigrants were examined at BBT on May 11 (46 d post-release) and throughout June 1992 (67-96 d post-release). Only 14 fish were captured, and of these only 10 were used for organosomatic examination. Due to the small sample size, significance of organosomatic and pathogen prevalence data for this study group should be considered with caution. ELISA showed 60% of the fish sampled to have *R. salmoninarum* antigen levels greater than 2 standard deviations above normal reference tissue, and 20% showed high enough levels of antigen as to support a positive designation (Table 10). The presence of the *R. salmoninarum* organism was confirmed by DFAT. Light metacercarial (presumptively *N. salmincola*) infection was observed in 1 of 12 kidney tissues examined by squash preparation. Glochidial infection was observed in 2 of 14 (1 of which was heavily infected) gills by histologic examination. Presumably, infection by these parasites occurred during the 46-96 d migration down to BBT. Intraluminal myxosporean parasites were observed in kidney sections from 3 of 10 fish. These histological sections were reviewed by Dr. Ron Hedrick (U.C. Davis Fish Pathologist) who concurred on the diagnosis of a myxosporean infection. An immunohistochemistry assay of the kidney tissue containing the myxosporean using a monoclonal antibody to 'PKX' (a myxosporean parasite of salmonid kidneys) did not produce a positive reaction (Dr. Ron Hedrick, pers. comm.).

Condition factor (K) of hatchery coho was significantly higher ($P < 0.01$) in fish sampled at IRG than at the trap (Table 11). Mesenteric fat was observed in 95% of the fish at IRG, but was seen in only 50% of the fish sampled at BBT. Reduction in (K) and mesenteric fat may be due to physical demands of migration, slow adaptation of the hatchery fish to natural forage, and metabolic demands of smoltification. Although plasma protein levels were shown to be significantly greater in the fish sampled at the hatchery than at the trap ($P < 0.01$), values measured at both sites were well within normal physiological range. A high level of scale loss was observed in greater than 10% of the fish sampled both at the hatchery and the trap. The effect of scale loss on the smolt's salinity tolerance is unclear, however, the empty scale pockets would likely increase ion permeability and provide sites of entry for pathogens. Smith (1982) discussed a report of salmon mortality in saltwater due scale-loss. If 30% or more of the juvenile salmon's scales were removed, mortality due abnormally high plasma Mg^{++} occurred within 24 hours. All fish sampled showed silver coloration.

Natural Coho

Natural coho emigrants were examined at BBT throughout May and June 1992 (Table 12). Only

12 fish were captured and frozen for later *R. salmoninarum* and parasite assays. Due to the small sample size, significance of pathogen prevalence data for this study group should be considered with caution. *R. salmoninarum* was not detected in these fish. Light metacercarial (presumptive *N. salmincola*) infection was observed in 1 of 11 of gill tissues sampled.

Organosomatic analysis of natural coho was not possible due to the low numbers of fish captured.

TABLE 10. Iron Gate Hatchery Coho Juveniles: Prevalence and incidence of virus infection in four fish pool kidney-spleen samples and Erythrocytic Inclusion Body Syndrome (EIBS) inclusions in individual blood smears. *Renibacterium salmoninarum* in individual fish kidney samples other bacteria in 2 fish kidney-spleen pools. Parasites in individual smears, wet mounts, and histological samples. Enzyme Linked Immunosorbent Assay (ELISA) and Direct Fluorescent Antibody Technique (DFAT) was used to detect *Renibacterium salmoninarum*. A total of 60 hatchery coho were sampled on March 9 at Iron Gate Hatchery (IRG) 17 d prior to release, and 15 adipose fin-clipped coho were sampled during emigration at the Big Bar Trap (BBT) on May 11 (46 d post-release), and throughout June (67-96 days post-release). Reported as number positive over number sampled (% positive)

	IRG	-----BBT-----		
		11MAY	JUNE	INCIDENCE
VIRUS	0/15 (0)	ND	ND	ND
EIBS	0/60 (0)	ND	ND	ND
BACTERIA				
<i>R. salmoninarum</i>				
ELISA: Antigen positive	6/60 (7)	2/10	ND	2/10 (20)
Antigen suspect	4/60 (10)	4/10	ND	4/10 (40)
DFAT:	4/60 (7)	3/8	0/2	3/10 (30)
<i>Yersinia ruckeri</i>				
	2/30 (7)	ND	ND	ND
<i>Aeromonas hydrophila</i>				
	4/30 (13)	ND	ND	ND
PARASITES				
Skin:	0/8 (0)	ND	ND	ND
Gill:				
<i>Trichodina spp.</i>	22/33(67)	0/12	0/2	0/14 (0)
<i>Trichophrya spp.</i>	0/33 (0)	1/12	0/2	1/14 (7)
Glochidia	0/33 (0)	2/12	0/2	2/14 (14)
Intestine:	0/30 (0)	0/8	0/2	0/10 (0)
Blood:	0/60 (0)	ND	ND	ND
Kidney:				
Metacercaria*	0/34 (0)	0/10	1/2	1/12 (8)
Myxosporean**	0/34 (0)	3/10	ND	3/10 (30)
ND	Not done.			
*	Presumptively identified as <i>Nanophyetus salmincola</i> .			
**	Unidentified intraluminal myxosporean parasite.			

TABLE 11. Iron Gate Hatchery Coho Juvenile Organosomatic Analysis Data: Twenty coho were examined on March 9 at Iron Gate Hatchery (IRG) 17 d prior to their release. Ten coho were examined on May 11, 1992 at the Big Bar Trap (BBT) 46 d post-release. Percentages reflect the number of fish in sample which meet the row criteria.

	IRG	BBT
CUMULATIVE ABNORMALITY SCORE	0.95	0.90
ABNORMAL TISSUES+	SKIN	SKIN
FAT LEVEL >0 (%)	95	50
SILVERED (%)	100	100

CONDITION FACTOR (k)		
mean	0.8394*	0.7105
std	0.0426	0.1548
cv	5.07	21.78
LENGTH (mm)		
mean	156.65	157.90
std	30.65	9.25
cv	19.56	5.86
WEIGHT (g)		
mean	37.11	27.51
std	25.32	3.35
cv	68.23	12.19
HEMATOCRIT		
mean	46.75	43.90
std	7.08	4.83
cv	15.14	10.99
PLASMA PROTEIN		
mean	5.67*	4.04
std	0.73	0.64
cv	12.88	15.78

* Significantly greater (P <0.01)

+ Tissues listed if >10% of sample had abnormal rating in that tissue.

std Standard deviation.

cv Coefficient of variation.

STEELHEAD

Hatchery Steelhead

Hatchery steelhead were examined on May 19, 1992 at IRG on the day of their release. A total of 60 fish were sampled. No significant viral or parasitic pathogens were detected in these fish (Table 13). ELISA showed 36% of the fish sampled to have *R. salmoninarum* antigen levels greater than 2 standard deviations above normal reference tissue, and 8% showed high enough levels of antigen as to support a positive designation. The presence of the *R. salmoninarum* organism was confirmed by DFAT. *Yersinia ruckeri*, the causative agent of ERM, was cultured from 27% of the fish sampled for bacteria. However, no clinical signs of ERM were observed in these fish. *Tricodina* (an invasive protozoan which may cause irritation when occurring in large numbers) were observed by wet mount and histological examination of gill tissues. *Ambiphyra* (filter feeding protozoans which use fish as a substrate), and *Gyrodactylus* (parasitic monogenetic trematodes which may cause irritation when occurring in large numbers) were observed by wet mount of skin mucus scrapings. It is doubtful that the level of parasitic infection observed at the hatchery had much of an effect on the fish's health.

Mesenteric fat and silver coloration was visible in all of the fish sampled (Table 14). As a historical interest, organosomatic analysis data from IRG steelhead examined in 1991 was included. It appears that the 1992 fish were larger than the 1991 release group. The 1991 release group received a very high AS which reflects poor fin condition in 100% of the fish examined and high degree of scale loss in 95% of the sample.

IRG steelhead were not sampled at BBT due to the low numbers of hatchery fish released, trapping efficiency, lack of distinguishing mark, difficulty in holding fish due to high water temperatures, and conflicting scheduled obligations as previously mentioned.

Natural Steelhead

Natural steelhead were examined on June 5, 1992 at BBT (Table 15). A total of 60 fish were sampled. No significant viral or bacterial pathogens were detected. Metacercarial (presumptively *N. salmincola*) infection was observed in 52% of kidney tissues, and 64% of gills examined by histological examination. Of the samples where metacercariae were found, 22% of gills and 17% of kidneys appeared to have a heavy infection. Lamellar cartilage damage was observed in histological examinations of the heavily infected gill samples. Focal glomerulonephritis (inflammation of the glomerulus) was observed in 1 of 9 kidney samples examined by histology, and was not associated with any parasites. Plasmodial stages of a myxosporean parasite were observed in the kidney glomerulus of 1 of 9 fish. No such parasites were seen in the kidney tubules. Meyers and McPherson (1985) reported similar glomerulonephritis and unidentified myxosporeans infecting the glomerulus of returning chinook adults in the Rogue river in Oregon.

Mesenteric fat was visible in only 40% of the fish sampled (Table 16). A high level of scale loss, presumably reflective of harsh livebox conditions, was observed in greater than 10% of the fish sampled. All fish sampled showed silver coloration.

TABLE 12. Natural Klamath River Coho Emigrants: Incidence of infection for parasites in individual smears, wet mounts, and histological samples. *Renibacterium salmoninarum* in individual fish kidney samples by Direct Fluorescent Antibody Technique (DFAT). A total of 12 natural coho were sampled during emigration at the Big Bar Trap throughout May and June 1992. Reported as number positive over number sampled (% positive).

	MAY	JUNE	INCIDENCE
BACTERIA			
<i>R. salmoninarum</i>	0/9 (0)	ND	0/9 (0)
PARASITES			
Gill:			
Metacercaria*	1/10 (10)	0/1 (0)	1/11 (9)
Intestine:	0/11 (0)	0/1 (0)	0/12 (0)
Kidney:	0/11 (0)	0/1 (0)	0/12 (0)
ND	Not done.		
*	Presumptively identified as <i>Nanophyetus salmincola</i> .		

TABLE 13. Iron Gate Hatchery Steelhead Juveniles: Prevalence of infection for Infectious Hematopoietic Necrosis Virus (IHNV) in 4 fish pool kidney-spleen samples and Erythrocytic Inclusion Body Syndrome (EIBS) inclusions in individual blood smears. *Renibacterium salmoninarum* in individual fish kidney samples, other bacteria in 4 fish kidney-spleen pools. Parasites in individual smears, wet mounts, and histological samples. Enzyme Linked Immunosorbent Assay (ELISA) and Direct Fluorescent Antibody Technique (DFAT) was used to detect *Renibacterium salmoninarum*. A total of 60 hatchery steelhead were sampled on May 19, 1992 at Iron Gate Hatchery on the day of their release. Reported as number positive over number sampled (% positive).

VIRUS	0/15 (0)
EIBS	0/60 (0)
BACTERIA	
<i>R. salmoninarum</i>	
ELISA: Antigen positive	5/60 (8)
Antigen suspect	17/60 (28)
DFAT:	1/60 (2)
<i>Yersinia ruckeri</i>	4/15 (27)
PARASITES	
Skin:	
<i>Ambiphyra spp.</i>	7/10 (70)
<i>Gyrodactylus spp.</i>	4/10 (40)
Gill:	
<i>Trichodina spp.</i>	14/26 (54)
Intestine:	0/30 (0)
Blood:	0/60 (0)
Kidney:	0/30 (0)

TABLE 14. Iron Gate Hatchery Steelhead Juvenile Organosomatic Analysis Data: Twenty steelhead were examined at Iron Gate Hatchery on the day of their release, May 19, 1992. Prior to the start of this study, 20 steelhead were examined on April 30, 1991. Data is provided for comparison. Percentages reflect the number of fish in sample which meet the row criteria.

	1992	1991
CUMULATIVE ABNORMALITY SCORE	0.35	2.35
ABNORMAL TISSUES+	THYMUS	FIN, SKIN
FAT LEVEL >0 (%)	100	100
SILVERED (%)	100	100

CONDITION FACTOR (k)		
mean	1.0601	1.0413
std	0.1122	0.0690
cv	10.58	6.63
LENGTH (mm)		
mean	188.10*	157.70
std	26.57	1.82
cv	14.13	5.59
WEIGHT (g)		
mean	74.41*	41.09
std	30.06	6.29
cv	40.39	15.30
HEMATOCRIT		
mean	45.15*	40.70
std	4.17	2.15
cv	9.25	5.28
PLASMA PROTEIN		
mean	5.87*	4.15
std	0.88	0.56
cv	15.07	13.53

* Significantly greater (P <0.01)

+ Tissues listed if >10% of sample had abnormal rating in that tissue.

std Standard deviation.

cv Coefficient of variation.

TABLE 15 Natural Klamath River Steelhead Emigrants: Prevalence of infection for Infectious Hematopoietic Necrosis Virus (IHNV) in 4 fish pool kidney-spleen samples and Erythrocytic Inclusion Body Syndrome (EIBS) inclusions in individual blood smears. Bacteria in 2 fish kidney-spleen pools. Parasites in individual smears, wet mounts, and histological samples. Direct Fluorescent Antibody Technique (DFAT) was used to detect *Renibacterium salmoninarum*. A total of 60 natural steelhead were sampled on June 5, 1992 at the Big Bar Trap. Reported as number positive over number sampled (% positive).

VIRUS	0/15 (0)
EIBS	0/60 (0)
BACTERIA	
<i>R. salmoninarum</i>	0/30 (0)
<i>A. hydrophila</i>	14/15 (93)
PARASITES	
Gill:	
Metacercaria*	18/28 (64)
Intestine:	0/38 (0)
Blood:	0/60 (0)
Kidney:	
Metacercaria*	15/29 (52)
* Presumptively identified as <i>Nanophyetus salmincola</i> .	

TABLE 16 Natural Klamath River Steelhead Emigrant Organosomatic Analysis Data:
Twenty natural steelhead were examined at the Big Bar Trap on June 5, 1992.
Percentages reflect the number of fish in sample which meet the row criteria.

CUMULATIVE ABNORMALITY SCORE		0.95
ABNORMAL TISSUES+		SKIN
FAT LEVEL >0 (%)		40
SILVERED (%)		100

CONDITION FACTOR (k)		
	mean	0.8733
	std	0.1058
	cv	12.11
LENGTH (mm)		
	mean	194.95
	std	24.38
	cv	12.51
WEIGHT (g)		
	mean	67.89
	std	27.15
	cv	39.99
HEMATOCRIT		
	mean	43.90
	std	4.67
	cv	10.63
PLASMA PROTEIN		
	mean	3.10
	std	0.71
	cv	22.76

+ Tissues listed if >10% of sample had abnormal rating in that tissue.

std Standard deviation.

cv Coefficient of variation.

SUMMARY

Results from the 1992 study indicate that *Renibacterium salmoninarum* the causative agent of bacterial kidney disease (BKD), *Nanophyetus salmincola* metacercaria, glochidia, and kidney myxosporean parasites are common pathogens to Klamath River salmonids some of which may impair the health of these fish.

BKD has long been a major limiting factor to salmonid hatchery success (Sanders and Fryer 1980). *R. salmoninarum* was positively detected by ELISA and confirmed by DFAT in a small percentage of IRG coho (7%) and IRG steelhead (2%) at the hatchery, and in IRG coho (30%) at BBT. *R. salmoninarum* was not positively detected in IRG chinook at the hatchery, at BBT, or in any natural stocks sampled at BBT. Clinical signs of BKD were not observed in any fish sampled during the study. Due to the low prevalence, lack of clinical signs in stocks where the bacteria were detected, and entire lack of detection in some groups, it appears that *R. salmoninarum* was not a significant factor to the health of emigrants in the Mid-Klamath River (Klamath River from IRG downstream to the confluence of the Trinity River) in 1992. The chronic nature of *R. salmoninarum* and its ability to cause disease in saltwater, could result in later BKD problems in "lightly" infected smolts (Banner et al. 1983). *R. salmoninarum* was positively detected by ELISA at a moderately high prevalence in chinook emigrants in the UE (25%) and the LE (6%). The higher prevalence and intensity of infection in the estuary compared to the Mid-Klamath may reflect a disproportionately high contribution of infected fish from the Trinity River to the estuary. Observations comparing samples collected in the Trinity River to those from the Mid-Klamath may support this possibility. The prevalence and intensity of *R. salmoninarum* infection in chinook salmon sampled in the Trinity River during the spring of 1992 was higher than that seen in fish from the Klamath River, but was not unlike that observed in Klamath estuary chinook. Further, the density of metacercarial organisms seen in kidney material from these fish was reminiscent of infections observed in chinook from the Trinity River (Foott, Walker unpub. data).

The high incidence and intensity (number of parasites per tissue, i.e. heavy infection) of *N. salmincola* infection observed in the chinook and steelhead smolts indicate that this parasite may be a significant health factor to Klamath river stocks. A similar situation occurs in the Trinity river (Foott and Walker, 1992). A negative correlation between high levels of *N. salmincola* metacercarial infection and saltwater survival has been documented in coho and chinook (Lee Harrell, NMFS, Manchester Marine Lab, WA, pers. comm.). Millemann and Knapp (1970) report that growth and swimming performance can be impaired by heavy *N. salmincola* metacercarial infection.

Myxosporean kidney parasites, seen in 34% of the fish collected at BBT and LE (natural steelhead, IRG coho, both IRG and natural chinook), did not appear to cause any lesions. There are several myxosporean parasites which are found in the kidneys of Pacific salmonids including *Chloromyxum majori*, *Parvicapsula sp.*, *Myxidium minteri*, and the 'PKX' *Sphaerospora sp.* responsible for Proliferative Kidney Disease (Yasutake and Wood 1957, Hoffman 1981, Kent and Hedrick 1985). Similar forms have been seen in steelhead smolts collected in the Trinity river (Foott and Walker, 1993). The failure of monoclonal antibody to 'PKX' to bind to the intraluminal forms suggests that they were not PKX. Unfortunately, no mature spores were observed which would facilitate identification.

Ceratomyxosis, the enteritis caused by *Ceratomyxa shasta*, can produce extensive mortality in susceptible strains of Pacific salmonids (Bartholomew et al. 1989). The infectious stage of this myxozoan parasite is endemic to the Klamath river, however, it is not found in the Trinity river (Hendrickson et al. 1989). The limited geographic distribution of the infectious stage of the

parasite may be related to specific environmental requirements of its intermediate host(s). One such intermediate host tentatively identified as a *Nais* worm which lives on the periphyton associated with freshwater mollusks (Bartholomew et al. 1992). Many salmonid strains, which have evolved in watersheds enzootic for *C. shasta*, are relatively resistant to the disease Ceratomyxosis (Ching and Parker 1989, Zinn et al. 1977). The traditional test for detection of the infectious stage involves placing susceptible salmonids in cages in the waters being studied. While this method can determine the presence of the infectious stage, it does not accurately model infection of emigrate stocks. Margolis et al. (1988) reported that although cage-exposure groups in the Fraser river experienced high infection rates and morbidity, surveys of natural emigrants showed low (1-3%) prevalence of infection. The lack of *C. shasta* spores detected in the Klamath river samples and low incidence rate observed in the estuary samples may be explained by several factors: 1) the conditions for infection were not present during the Spring of 1992, 2) the Klamath river stocks examined are resistant to Ceratomyxosis, and 3) the emphasis of spore detection from frozen samples could have missed earlier developmental stages of the parasite and therefore underestimated infection rate. We did not observe clinical signs of Ceratomyxosis in any of the fish sampled during the study. It appears that Ceratomyxosis was not a prevalent disease in the emigrant fish during 1992.

Future studies should utilize more fixed tissue samples, which would allow collection of sufficient numbers of samples as the fish are trapped, reducing the necessity of timing sample collection with peak migration. Limiting sampling at BBT and the Klamath estuary to strictly coded wire tagged fish would allow stronger conclusions about the relationship between pathogen prevalence and origin or life history. Salmon must undergo physiological changes prior to entry into saltwater. A number of biochemical changes, such as elevation in concentration of gill $\text{Na}^+ - \text{K}^+$ -Adenosinetriphosphatase (ATPase) and increased ability to regulate plasma sodium while in saltwater, have been utilized as physiological indices of smoltification (Zaugg 1991). Knowledge of smoltification physiology could provide information valuable to interpretation of return data on these fish.

SIGNIFICANT RESULTS

- 1) *Renibacterium salmoninarum*, the causative agent of BKD, was detected in a small percentage of IRG coho (7%) and IRG steelhead (2%) at the hatchery and also in IRG coho (30%) at BBT. Moderately high prevalence of *R. salmoninarum* was detected in mixed chinook stocks in the Klamath estuary.
- 2) The high incidence and intensity (number of parasites per tissue, i.e. heavy infection) of *N. salmincola* infection observed in the chinook and steelhead smolts indicate that this parasite may be a significant health factor to Klamath river stocks.
- 3) Light glochidial infection was observed in IRG chinook, coho and natural chinook at BBT and chinook in the estuary. Glochidia were not detected in natural coho or any steelhead examined.
- 4) No viral agents including viral blood inclusions were detected in any of the fish examined.
- 5) An unidentified myxosporean parasite was observed in IRG coho, IRG chinook, natural chinook, and natural steelhead at BBT, and in chinook sampled in the LE. Attempts to identify this organism serologically were unsuccessful.
- 6) *Ceratomyxa shasta* spores were detected in the intestine of 6% of the LE chinook examined. Although endemic to the Klamath River Basin (Hendrickson et al. 1989), this myxosporean parasite was not detected in any other fish examined in the study. Future studies should utilize histological techniques to detect early stage infection.

7) All IRG groups examined at BBT showed signs typical of smolt migration such as reduced mesentery fat, reduced condition factor, and silver coloration.

REFERENCES

- Banner, C.R., J.S. Rohovec, and J.L. Fryer. 1983. *Renibacterium salmoninarum* as a cause of mortality among chinook salmon in saltwater. *J. World Mariculture Soc.* 14:236-239.
- Bartholomew, J.L., J.S. Rohovec, and J.L. Fryer. 1989. *Ceratomyxa shasta*, a myxosporean parasite of salmonids. *Fish Disease Leaflet 80*, U.S. Fish and Wildlife Service.
- Bartholomew, J.L., J.S. Rohovec, and J.L. Fryer. 1992. *Ceratomyxa shasta* infection of salmonid fishes. Pages 267-270 in: *Proceedings of OJI International Symp. of Salmonid Diseases*. Hokkido University Press, Sappairo, Japan.
- Bjornn, T.C. 1977. Wild fish production and management. *American Fisheries Society Special Publication 10*: 65-71.
- California Advisory Committee on Salmon and Steelhead Trout. 1988. *Restoring the Balance*, a report to the Legislature and the Department of Fish and Game. 84 pages. No. 124-J., Sausalito, CA.
- Ching, H.L. and L. Parker. 1989. Experimental exposure of trout and salmon from 12 British Columbia stocks to the myxozoan parasite *Ceratomyxa shasta*. *J. Aquatic An. Health*, 1:205-208.
- Craig, J. 1991. Annual report: Klamath river basin juvenile salmonid fisheries investigation 1989. Report No. AFF-1 FRO 91-3, U.S. Fish & Wildlife Service, Coastal California Fishery Resource office, Arcata, California. pp 81.
- Farrell, R.K., M.A. Lloyd and B. Earp. 1964. Persistence of *Neorickettsiae helminthoeca* in an endoparasite of the Pacific salmon. *Science* 145:162-163.
- Foott, J.S. 1990. The organosomatic analysis system: A tool for evaluation of smolt quality. In: *Proceedings of the Northeast Pacific chinook and coho salmon symposium*, September 18-22, 1990, Arcata, California.
- Foott, J.S. and R.L. Walker. 1992. Disease survey of Trinity River salmonid smolt populations - 1991 Report. CA-NV Fish Health Center, U.S. Fish and Wildlife Service, Rt. 1, Box 2105, Anderson CA, 96007.
- Foott, J.S. and R.L. Walker. 1993. Health and Physiological assessment of steelhead and chinook smolts in the Trinity River - 1992 Report. CA-NV Fish Health Center, U.S. Fish and Wildlife Service, Rt. 1, Box 2105, Anderson CA, 96007.
- Goede, R. W. and B. A. Barton. 1987. Organismic indices and autopsy-based assessments as indicators of health and condition in fish. Pages 93 - 108 in S. M. Adams editor, *Biological Indicators of stress in fish*. American Fisheries Society, Bethesda, Maryland.
- Hedrick, R.P., S.E. LaPatra, J.L. Fryer, T. McDowell, and W.H. Wingfield. 1987. Susceptibility of Coho (*Oncorhynchus kisutch*) and Chinook (*Oncorhynchus tshawytscha*) salmon hybrids to experimental infections with Infectious Hematopoietic Necrosis Virus (IHNV). *Bull. Eur. Ass. Fish Pathol.* 7(4):97-100.
- Hendrickson, G. L., A. Carleton, and D. Manzer. 1989. Geographic and seasonal distribution of

- the infective stage of *Ceratomyxa shasta* (Myxozoa) in Northern California. *Diseases of Aquatic Organisms* 7: 165-169.
- Hoar, W.S. 1988. The physiology of smolting salmonids. Pgs. 275-343. *in* W.S. Hoar and D.J. Randall eds., *Fish Physiology Vol XI, Part B*, Academic Press, New York.
- Hoffman, G. L. 1970. *Parasites of North American freshwater fishes*. University of California Press, Berkeley.
- Hoffman, G.L. 1981. Two fish pathogens, *Parvicapsula* sp. and *Mitraspora cyprini* (Myxosporaea), new to North America. *In: Fish, pathogens and environment in European polyculture*, Szarvas, Hungary. pp 184-197.
- Jennings, M.R. and G.L. Hendrickson. 1982. Parasites of chinook salmon (*Oncorhynchus tshawytscha*) and coho salmon (*O. kisutch*) from the Mad river and vicinity, Humboldt county, California. *Proc. Helminthol. Soc. Wash.* 49(2):279-284.
- Karna, D.W. and R.E. Millemann. 1978. Glochidiosis of salmonid fishes. III. Comparative susceptibility to natural infection with *Margaritifera margaritifera* (L.) (Pelecypoda: Margaritanidae) and associated histopathology. *J. Parasitol.* 64(3): 528 -537.
- Kent, M.L. and R.P. Hedrick. 1985. PKX, the causative agent of proliferative kidney disease (PKD) in Pacific salmonid fishes and its affinities with Myxozoa. *J. Parasitol.* 32:254-260.
- Manzer, D. 1991. BKD - California experience. Abstract. Page 65. *in* S. Mangin ed., *National workshop on bacterial kidney disease*, Phoenix, Arizona, Nov. 19-21, 1991, U.S. Fish and Wildlife Ser., Arlington, VA.
- Margolis, L. , T.E. McDonald, and D.J. Whitaker. 1988. Is Ceratomyxosis a major cause of mortality of Fraser river (British Columbia) juvenile chinook salmon (*Oncorhynchus tshawytscha*)? Abstract from : *International Fish Health Conference*, Vancouver, B.C., Canada, July 19-21, 1988. pp 112.
- Meyers, T.R., R.E. Millemann, and C.A. Fustish. 1980. Glochidiosis of salmonid fishes. IV. Humoral and tissue responses of coho and chinook salmon to experimental infection with *Margaritifera margaritifera* (L.) (Pelecypoda: Margaritanidae). *J. Parasitol.* 66:274-281.
- Meyers, T.R. and B.P. McPherson. 1985. Chronic glomerulonephritis in returning fall chinook salmon, *Oncorhynchus tshawytscha* (Walbaum), from the Rogue river, Oregon. *J. Fish Dis.* 8:407-416.
- Millemann, R.E. and S.E. Knapp. 1970. Pathogenicity of the "salmon poisoning" trematode *Nanophyetus salmincola* to fish. Pages 209 - 217 *In: S.F. Snieszko, ed. A symposium on diseases of fishes and shellfishes. Special Publ. No. 5* , American Fisheries Society, Washington D.C..
- Pascho, R.J., and D. Mulcahy. 1987. Enzyme-linked immunosorbent assay for a soluble antigen of *Renibacterium salmoninarum*, the causative agent of salmonid bacterial kidney disease. *Can. J. Fish. Aquat. Sci.* 44:183-191.
- Piper, R. G., I. B. McElwain, L. E. Orme, J. P. McCraren, L. G. Fowler, and J. R. Leonard. 1982. *Fish Hatchery Management*. U. S. Department of the Interior, Fish and Wildlife Service, Washington, D.C..
- Sanders, J.E. and J.L. Fryer. 1980. *Renibacterium salmoninarum* gen. nov., sp. nov., the causative agent of bacterial kidney disease in salmonid fishes. *Int.J. of Systemic Bacteriol.*

30(2):496-502.

- Slauson, D., B. Cooper. 1982. Mechanisms of disease, a textbook of comparative general pathology. Williams and Wilkins, Baltimore.
- Smith, L. S. 1982. Introduction to Fish Physiology. T.H.F. Publication Inc., new Jersey, pg 313.
- Wood, E.M. and W.T. Yasutake. 1956. Histopathology of fish. II. The salmon-poisoning fluke. Prog. Fish-Cult. 18: 22-25.
- Yasutake, W.T. and E.M. Wood. 1957. Some myxosporidia found in Pacific Northwest salmonids. J. Parasitol. 43(6): 633-642.
- Young, C.L. and G.B. Chapman. 1978. Ultrastructural aspects of the causative agent and renal histopathology of BKD in brooktrout (*Salvelinus fontinalis*). J. Fish. Res. Bd. Can. 35:1234-1248.
- Young, M. and J. Williams. 1984. The reproductive biology of the freshwater pearl mussel *Margaritifera margaritifera* Linn. in Scotland. II. Laboratory studies. Arch. Hydrobiol. 100:29-43.
- Zaugg, W.S., W.W. Dickhoff, B.B. Beckman, C. Mankin, G. Winans, T.W. Newcomb, C.B. Schreck, A.N. Palmisano, R.D. Ewing and C.W. Hopley. April 1991. Smolt quality assessment of spring chinook salmon. BPA project No. 89-046.
- Zinn, J.L., K.A. Johnson, J.E. Sanders, and J.L. Fryer. 1977. Susceptibility of salmonid species and hatchery strains of chinook salmon (*Oncorhynchus tshawytscha*) to infections by *Ceratomyxa shasta*. J. Fish. Res. Board Can. 34(7):933-936.

APPENDIX 1.

ORGANOSOMATIC METHODOLOGY

The organosomatic analysis system used in this study was modified from Goede's Fish Health and Condition Assessment System (Goede and Barton 1987). The system is a method for ordered observation and reporting of the gross morphology of selected organs, hematological measurements, and size criteria. A twenty fish sample collected in an unbiased manner from the population of interest is sufficient for the system (Goede and Barton 1987).

Goede's system was modified to better suit smolt evaluation needs and allow for comparison between temporally and geographically different juvenile fish populations of the same age and species. Leukocrit was removed from the nominal data group (length, weight, hematocrit, and plasma protein) which is analyzed by parametric statistics, and placed in with the subjective tissue and organ categories. Leukocrit is the packed volume of white blood cells in a microhematocrit sample (referred to as the buffy coat). Fish blood samples have relatively small buffy coats that require the use of a low power, ocular micrometer for accurate measurement (Wedemeyer et al. 1983). This microscopic procedure is tedious and time consuming. In Goede's system, leukocrit is roughly estimated with a hematocrit tube reader. Fin condition, skin condition, and degree of silver coloration/loss of parr marks (external sign of smoltification) were added to the examination list. Finally, the descriptive categories for each tissue or organ observation were qualified numerically to assess the severity of the observed abnormalities and summed to give each smolt a gross "abnormality" score. A low abnormality score reflects a fish in good condition.

In Goede's current system, a wide variety of abnormality codes are used to describe each organ or tissue. His report format lists all the observations which match each abnormality code as well as a summary of percent normal observations for each organ and tissue. This emphasis on observational percentages makes comparing multiple samples (populations) tedious. A mean abnormality score for the sample provides the user with a single value that could be quickly compared to other populations.

A separate weighed fitness score is derived from weight factors multiplied by each organ's severity score. Each organ or measurement would be weighted by a factor, according to its perceived importance in saltwater adaptation and emigration, as follows: 0 (not included in scoring), 1 (minor), 2 (medium), and 3 (major). For example, kidney abnormalities would be weighed more (3X) than fin condition (1X) since the kidney is critical to divalent ion regulation, a process necessary for successful saltwater adaptation. The spreadsheet report allows for easy changes in weight factors. A description of the weight factors is listed below.

Organ-Measurement	Weight Factor	Importance/Comments
FIN	1X	
SKIN	2X	Scale loss increases osmotic disfunction.
GILL	3X	Na-K-ATPase needed for saltwater adaptation.
PSEUDOBRANCH	1X	
THYMUS	1X	
SMOLT INDEX	0X	Silver color does not ensure saltwater adaptation.
LIVER	2X	Glycogen and lipid metabolism for energy.
SPLEEN	2X	Immune defenses.
KIDNEY	3X	Divalent ion excretion, blood formation.
GASTRO-INTEST.	2X	Lower intestine involved in ion regulation.

FAT = 0	0X	Natural smolts rarely have mesenteric fat.
HCT < 20 %	2X	Abnormally low hematocrit (anemia).
Pl. PRO <2.0 g/dL	2X	Abnormally low plasma protein (hypoproteinemia).

EXAMINATION PROTOCOL

- 1) Fish are euthanized with an overdose of MS-222, and immediately bled from an incision in the caudal peduncle. Care is taken not to cut off the tail. Blood is collected in a heparinized microhematocrit tube, centrifuged at 10,000 rpm for 5 min., and measurements taken within 10 minutes. Once the packed erythrocyte volume (hematocrit) is determined with a tube reader and the leukocrit (packed volume of white blood cell or buffy coat) is estimated with the tube reader, the tube is broken at the cell - plasma interface. Plasma is expressed into a serum refractometer chamber for protein concentration determination.
- 2) Fish are kept in order for all observations and measurements. While the blood samples are being centrifuged, the condition of the eyes, fins, skin (especially loss of scales), gills, pseudobranchs, thymus, and degree of silvering/loss of parr marks is determined for all fish.
- 3) An incision is made from the branchial cavity to the anus. Disruption of internal organs is avoided. The condition of the liver, spleen, kidney, gastro-intestinal tract, and the amount of mesenteric fat is recorded for each fish.
- 4) Total length (mm), and body weight (g) is recorded for each fish. From these parameters, condition factor ($\text{wt.} \times 10^5 / \text{tot. length}^3$) is calculated. Fish undergoing smoltification typically show a decrease from "normal" in this index.
- 5) Samples for microbiological assays are collected.

SMOLT ORGANOSOMATIC ANALYSIS SCORE CRITERIA

Sample size = twenty fish.

Continuous Nominal Data: Mean, standard deviation, and coefficient of variation calculated.

Total Length millimeters (Snout to tip of tail)

Weight grams

Condition Factor (K) $\frac{\text{Weight} \times 10^5}{(\text{Tot. Length})^3}$

Hematocrit Vol. RBC Pack / Blood Sample Vol. x 100
(x 2 IF < 20 %) (Centrifuge 5 Min. @ 10,000 RPM)

Plasma Protein grams/deciliter (total protein triple scale
refractometer)
(x 2 IF < 2.0 g/dL)

Subjective Ordinal Data: (Severity score X weight factor)

Fins (x 1) 0 - NO ABNORMALITY, WELL SHAPED
(SOME OR ALL) 1 - DISCOLORED, CLUBBED, FRAYED, <30 % EROSION
2 - >30 % EROSION BUT STILL VISIBLE
3 - ERODED TO THE BASE OR HEMORRHAGING

Skin (x 2) 0 - NORMAL COLORATION AND SCALE NUMBERS
1 - DARKEN/HIGH MUCUS AMT., <30 % SCALE LOSS
2 - ABRASION, FUNGAL INFECTION, >30% SCALE LOSS
3 - OPEN LESIONS

Eyes (x 3) 0 - NO ABNORMALITIES
DIMINUTIVE 1 - CATARACTS, PARASITES, MISSING ONE EYE,
2 - EXOPHTHALMOS
3 - HEMORRHAGES

Gills (x 3) 0 - NORMAL COLORATION AND LAMELLAR
STRUCTURE 1 - PALE (ANEMIA)
2 - CLUBBED (SL. HYPERPLASIA), FRAYED AT TIP,
NODULES 3 - FUSED LAMELLAE, HEMORRHAGING, NECROTIC

Pseudobranchs (x 1) 0 - NORMAL COLORATION AND STRUCTURE
1 - SWOLLEN AND/OR LITHIC
2 - HEMORRHAGES
3 - NECROTIC

Thymus (x 1) 0 - NORMAL COLORATION AND STRUCTURE
1 - FEW PETECHIAL HEMORRHAGES
2 - MODERATE HEMORRHAGING

3 - NECROTIC

Silvering (x 0)	0 - FULLY SILVER, NO PARR MARKS VISIBLE 1 - SILVER WITH FAINT PARR MARKS 2 - HINT OF SILVER WITH DISTINCT PARR MARKS 3 - NO SILVERING
Leukocrit (x 0)	0 - NOT VISIBLE OR <2.0 UNIT ON TUBE READER 1 - >2.0 UNITS ON TUBE READER (LEUKOCYTOSIS)
Subjective Ordinal Data Continued: (severity score X weight factor)	
Liver (x 2) TO TOUCH	0 - NORMAL SIZE, RED OR LIGHT RED 1 - PALE OR YELLOW COLORATION AND/OR "FATTY" 2 - NEMATODES, FOCAL DISCOLORATION 3 - LESIONS (NODULES, HEMORRHAGING)
Spleen (x 2)	0 - NORMAL SIZE, RED OR DARK RED IN COLOR 1 - ENLARGED 2 - FOCAL DISCOLORATION, LESIONS PRESENT 3 - "LIQUIFIED" STATE, SEVERE HEMORRHAGING
Kidney (x 3) "LIQUIFIED"	0 - NORMAL SIZE , VENATION APPARENT 1 - NEPHROCALCINOSIS, PALE (ANEMIA) 2 - SWOLLEN, NORMAL RED COLORATION 3 - NODULES, GREY SWOLLEN APPEARANCE, OR
G.I. Tract (x 2) FLUID	0 - NORMAL COLORATION & MORPHOLOGY (FOOD +/-) 1 - YELLOW CATARRHAL EXUDATE 2 - MILD HEMORRHAGING 3 - SWOLLEN & HEMORRHAGIC, STOMACH FILLED W/
Mesentery Fat (x 0) PC PC FAT	0 - NONE IN PERITONEAL CAVITY (CAV) OR ON PYLORIC CECA (PC) 1 - CAV FAT < DIA. OF PC AND/OR <50% COVERAGE OF 2 - CAV FAT = DIA. OF PC AND/OR >50% COVERAGE OF 3 - CAV SOLID WITH FAT AND/OR PC OBSCURED BY

APPENDIX 2.

ORGANOSOMATION DATA REPORTS